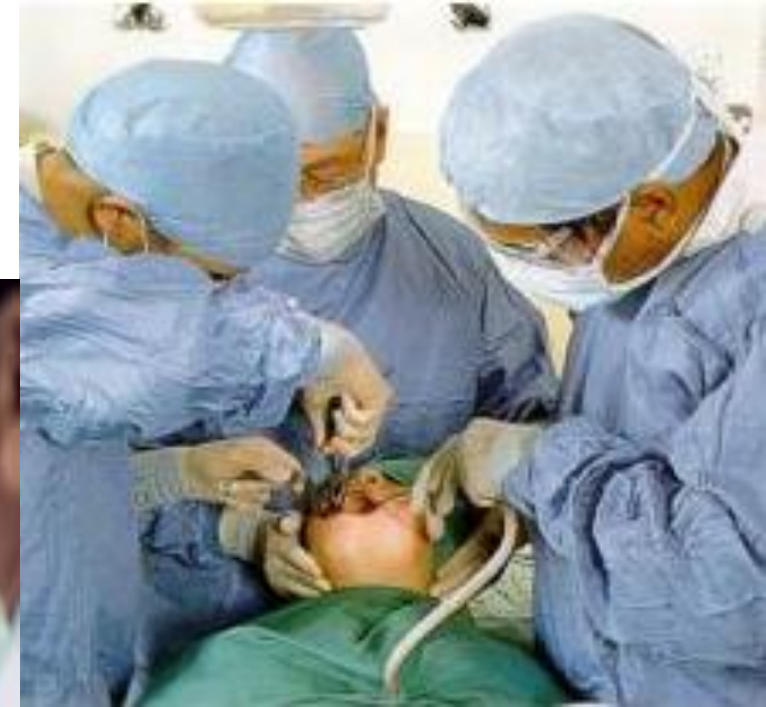
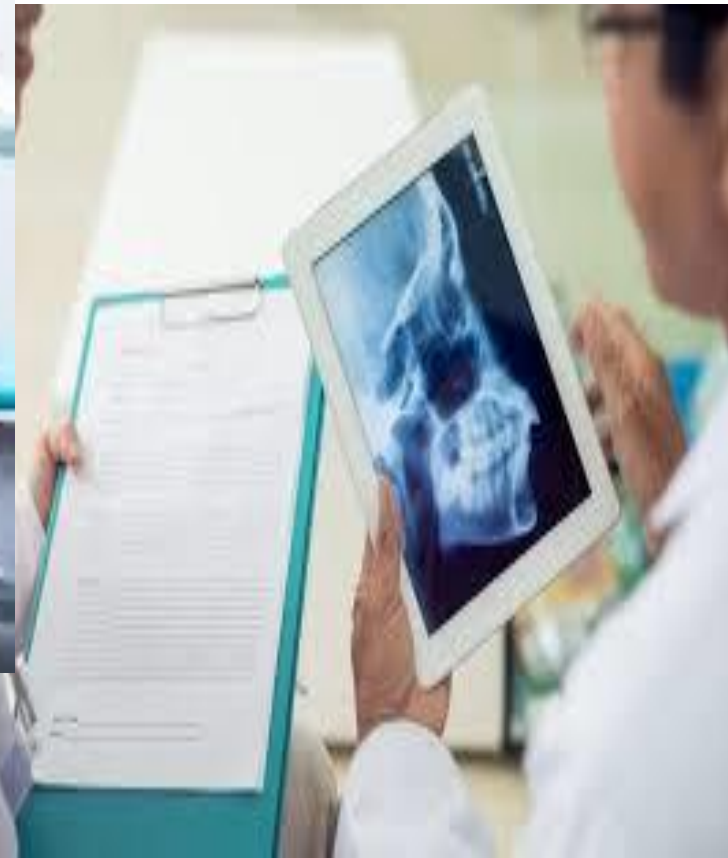
# *Surgical Diagnosis in Oral Surgery*



## **Oral and maxillo-facial surgery :**

Is one of the dental specialties dealing with management of diseases, injuries and defect of human jaws and associated structures .

maxillofacial surgery form the connecting link between medical and dental specialties .

## **Diagnosis in surgery:**

Oral diagnosis is the art of using the scientific knowledge to identify the oral diseases and also to distinguish one disease from another. The diagnostic process classically involves the following steps:-

1- History taking. 2- Clinical examination. 3- Investigation. 4- Provisional diagnosis. 5- Definitive diagnosis and treatment plan.

**In oral surgery practice, clinician is often faced with the diagnosis of the following conditions:-**

1- Dental and facial pain. 2- Swelling (lump, mass). 3- Ulcers;  
4- Injuries (dental, facial bones). 5- Temporomandibular joint problems. 6- Medically compromised patient.  
7- Facial deformity.

## **History taking :**

The art of taking an accurate case history is probably the most important single step in the diagnosis of medical or surgical condition .History taking should be systematic , using special set or sequences . During history taking the clinician or the dental surgeon listen to the patient`s story or talks and list the symptoms in order of severity or importance . **By patient`s words .**

## **Objective of taking History :**

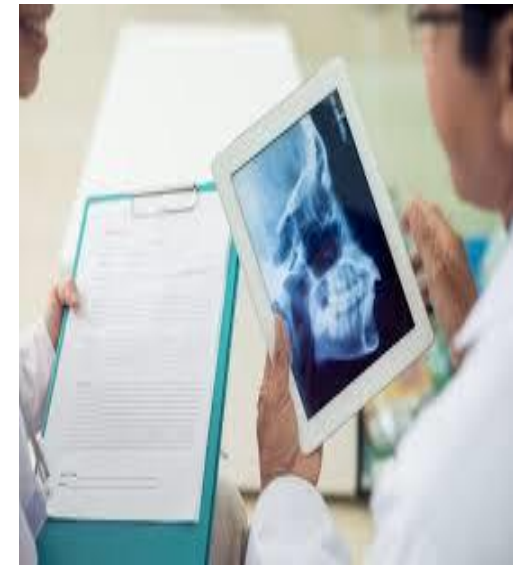1. To provide dentist with information's that may be necessary for making diagnosis.
2. To establish a good or positive professional relationship with the diagnosis which affect cooperation and confidence .
3. To provide dentist with information's concerning patient`s past and present medical , dental and personal history .
4. To provide information's about patient`s systemic health which may greatly affect the treatment plan and prognosis and disease that could be transmitted to the dentist , his staff or other patients .
5. It serves as a legal document .

## **Symptoms :**

Means a subjective problem that patient describes e.g. pain, paresthesia .

## **Signs :**

Means (objective) an abnormal presentation detectable by the clinician e.g. swelling , ulcer .



# History Taking Format

- Chief complaint
- History of present illness (HPI)
- Past medical history, which includes
  - Childhood
  - Medical
  - Surgical
  - OB/GYN
  - Psychiatric
- Family history
- Medications
- Allergies
- Personal/social history
- Review of systems



## *How you taking history :*

During history taking dentist should **encourage** his patient to describe his symptoms in his own words , interrupting his story only to explain a point or stop a useless talk .

A clear and concise summary of patient`s complaints should be recorded or being listed in order of its importance (e.g. pain , swelling , bleeding ) .

During taking the history give your patient your while whole attention and never take shortcuts .

You have a **void speed** in taking the history , so you have give the patient a suitable time to give all information , because hurry in taking history may lead to many pitfalls that affect the accuracy or completeness .

You have a **void the leading questions** (e.g. dose the pain comes on taking hot or cold ?) it`s better to ask him what is or what are the thing that **brings pain to you** ? Or any thing hurt you ?

During taking history don`t **depend on the patient diagnosis** or **the diagnosis of the previous doctor** , so you have to ask the patient to **describe his complaining only to establish your diagnosis** .

## *Components of the patient history :*

The case history may include commonly the following sections or component :

1. Biographic data (personal history) .
2. Chief complaint (c.c).
3. History of present illness ( H.P.I.)
4. Past dental history and past medical history.
5. Medical history and systems review .
6. Family history .



## **Biographic data :**

Include the full name of the patient , age , sex , address and telephone number and occupation . these information's may **aid** or **contribute to the diagnosis** since some medical problems have a tendency to occur in a particular age group ,sex or race . The patient **occupation maybe associated with a particular disease** or may **influence the type of therapy**

## **Chief complaint (c.c):**

The Chief complaint is usually the reason for the patient`s visit .

The Chief complaint(s) is best stated in the patient`s **own words** in a brief summary of the problems (e.g. pain , swelling ,ulcer, paresthesia , numbness , clicking , halitosis , bleeding ,trismus ) . if the patient complaining of several symptoms in which case they should be listed , but with the major complaint first.

## **History of the present illness ( H.P.I. ):**

This part of the story must be gone into complete detail and get the patient to tell the story in his fashion , never ask the patient leading questions and you have to see if the patient in a condition able to give you a history which is reliable and his statement ,can be relied upon .

## **It`s best to start by asking the patient about :**

- 1.Duration (record the length of the complain) . ,
2. Onset (data of onset , manner of onset ) .
3. Precipitating /predisposing factors.(e.g. hot ,cold, sweet). ,
4. Characteristic , and this include :
  - a) Nature e.g. (continuous , intermitted , stabbing).
  - b) Severity (e.g. mild ,moderate, sever , very sever ) .
  - c) Location .
  - d) Radiation (feeling of pain in site other than that of causative lesion , called **referred pain**).
  - e) Aggravating factors .

f) Relieving factors . g) Associated constitutional symptoms and signs .

5. Course and progress .

6. Therapy : a) Type of therapy and dose ., b) Provider ., c) Effect of therapy . d) Date of therapy .

## 7. Other information .

So if a patient comes with a chief complaint (pain) very detailed history of the pain should be taken and particular attention paid to the following points :

a) The duration of pain : Whether any incident which might have played some part in the etiology of the pain precede its onset (e.g. a blow on the jaw dental treatment) , duration record the length of the pain .

b) Site of the pain : the patient should be asked to point to the place where the pain is felt , using his finger .

c) Any radiation of the pain : if the pain radiates , the patient should be asked to demonstrate its course with the tip of his finger . On other occasions pain maybe felt in a site other than of the causative lesion or remote from the diseased area and this type called "referred pain" , e.g. **pain of pericoritis radiate to the ear .**

d) The precise characteristic of the pain : the pain maybe described as sharp , sever , dull, throbbing , excruciating lancinating , mild , continuous , intermitted, all these objectives can be applied to the pain in different pathological process which may help you in the diagnosis . (In acute pulpitis , the pain is dull, throbbing and sever and the tooth tender , in acute maxillary sinusitis the pain is dull, throbbing and continuous ).

e) Timing of pain : some pains are characteristically worse at particular time in the day e.g. pulpal pain often wakens the patient at night and tend to keep him awake , in acute periodontitis the pain is worse at meal time .

f) Any factors which precipitate the pain : pulpal pain is often precipitated by thermal and osmotic stimuli (hot ,cold ,sweet ) . Periodontal pain often precipitated by biting and chewing .

f) Any factors which precipitate the pain : pulpal pain is often precipitated by thermal and osmotic stimuli (hot ,cold ,sweet ) . Periodontal pain often **precipitated by biting and chewing .**

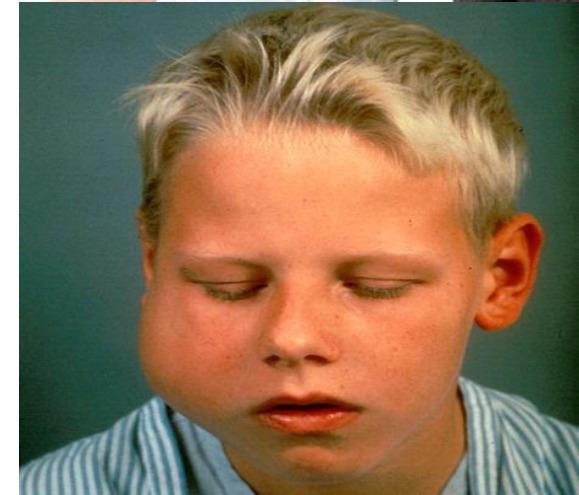- g) Any factors or drugs which relieve pain : this will give you an idea about the nature and duration of severity of the pain .
- h) The presence of other symptoms : Like the patient that says that , the pain starts for two days , than a swelling appeared after that or discharging sinus appear or discharging of pus , or pain , swelling then parasthesia of the lower lip ...etc.
- i) The patient also may be asked about relevant past medical history which may assist you on the diagnosis of the pain like patient with facial pain of vascular origin like migraine, or chronic psychosomatic origin or angina (**angina pectoris** )pain .In addition to that the patient asked about his opinion of the cause of the pain .

### *Patient presented with a "lump or mass":*

The oral surgeon must be ascertained by asking some questions: -

- 1- How long the swelling has been present.
- 2- Whether it is getting larger or smaller or fluctuated in size.
- 3- What are the symptoms of the lump: The lump maybe painful or not. If the lump is associated with Parasthesia or numbness of the lower lip for example.
- 4- Whether there is any possible cause for the swelling e.g. trauma, injuries, or systemic illness known to the patient.
- 5- What made the patient notice the lump?

By feeling or because it is painful or someone else noticed it and told him.



## **Past dental history (P.D.H):**

### **The past dental history includes:**

- 1- The frequency of previous visits (e.g. previous extractions or oral surgical procedures).
- 2- Any difficulties or complications (e.g. excessive bleeding or fainting).
- 3- Determination of the availability of past dental or oral radiographs. In other words, it is important to ask the patient about any type of dental or oral treatment received before, and if there is any complications or unsatisfaction arise and his impression about the type of treatment. **Medical history and systems review (M.H):-**

The patient's medical history includes review, the past and the present illness or diseases because:-

- 1- These information (M.H) may aid in the diagnosis of various conditions occurring or has oral manifestation that are related to specific systemic disease (e.g. aids, leukemia).
- 2- The presence of many diseases may lead or need modification for the treatment plan, and affect the manner in which therapy is provided.
- 3- Drugs used in treatment of some systemic diseases can also have effects on the mouth (have oral manifestation), or dictate some modification to the dental or surgical treatment (e.g. anticoagulant drugs, chemotherapy).

## *The past medical history includes:*

1- Previous serious illness or diseases. 2- Childhood diseases.

3- Hospitalization.

4- Operations.

5- Injuries to the head and neck.

6- Allergy to drugs or general allergy.

7- Listing of medication taken in the last six months. **Some examples of serious illness:-** ♦ Heart attack or diseases (e.g. myocardial infarction, angina pectoris).

♦ Stroke (cerebrovascular accident C.V.A). ♦ Hypertension. ♦ Heart failure. ♦ Bleeding disorders. ♦ Diabetes. ♦ Rheumatic fever or disease. ♦ Hospitalizations may indicate past disease and how it was treated. ♦ Aids (acquired immune-deficiency syndrome). ♦ Viral hepatitis. ♦ Neoplasm and the method of treatment (surgical, cytotoxic drugs) especially if the growth in the head and neck region **or** previous radiation (radiotherapy). ♦ Allergic reaction to drugs.

## *Review of the systems:*

Is that part of medical history covering each major system of the body.

**Review of systems lead to concentration on the signs and symptoms related to that system disorders,** which dictate us to more investigations or referring of the patient for medical evaluation and preparation.

**The review of systems includes:**

Cardio vascular system, respiratory system, central nervous system, genitourinary system, musculoskeletal system, endocrine system, ears, eye, vital signs (blood pressure, pulse, temperature, respiratory rate).

## Components of medical history :

Any patient come to you should be asked certain concise questions that aid you to have medical history, and this includes: 1. If he is currently receiving any medical care or under supervision of any clinician. 2 . Whether he has been hospitalized and Why? 3 . If you have any serious illness remembered by the patient? 4 . If you have any surgical operation before?

9

5 . If your patient takes any type of drugs before in the past or present time?

## **Family History: (F. H.)**

Details of (F.H.) may reveal valuable information about diseases that are occurring in families (e.g. Tuberculosis, Hemophilia, Psychiatric or neurotic disorders, Breast cancer) Congenital Anomalies such as lip clefts or palate clefts.

**Clinical Examination** Careful history taking should be followed by a thorough and systematic clinical examination.

## **Clinical Examination includes:**

1 . Extra oral Examination.

2 . Intra oral Examination: In extra oral examination we consider the general evaluation e.g. Observation the patient Posture, Gait, Facial Form, Nutrition Status, Speech, Body movement, Skin, Hair, Vital Signs. In addition to that we examine the area of the head and the neck thoroughly and **this includes:**

Examination of the Temporomandibular Joint. -Lymph Nodes. -Salivary Glands. -Bones of the Skull.

# Methods of Clinical Examination:

In Clinical practice, examination of patient involves FOUR ROUTINE PROCEDURES

**1. INSPECTION. 2. PALPATION. 3. PERCUSSION. 4. AUSCULTATION.**

**INSPECTION (VISUAL) :-** At the start of every examination you must begin by Looking at patient as a whole before looking at the region in question for signs that may provide clue for a Diagnosis any changes in the color, or asymmetry of the face and sclera of the eyes, any growth, ulceration, Scar, Defect, Loss of tissue should be inspected by your eye.

**PALPATION:-**Next use your fingertips to feel for tender spots , Lump , Fluctuant Swelling , & Mobile teeth . Palpation gives information about texture, Dimension, consistency, Temperature & Functional Events .

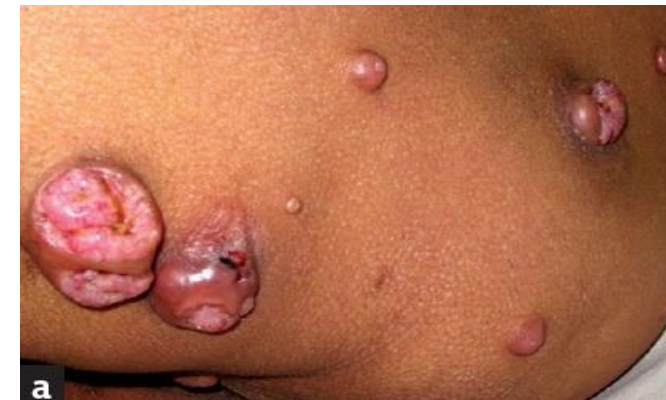**PROBING:** Is the palpation with an **instrument & is one of the most important diagnostic techniques used in Dentistry**. The teeth are probed for caries with the dental probe & periodontal probe is used to measure the periodontal sulcus depth. Lacrimal probe used for examination of parotid & submandibular salivary gland ducts. Fistulous tracts can be probed with **Gutta Percha points** to determine the **origin of the Fistula**

**PERCUSSION:** Is the technique of striking the tissue with fingers or an instrument (e.g. Handle of the mirror). The examiner listens to the resulting sounds & observes the response of the patient. Extra orally, percussion is often used to detect tenderness in the frontal and maxillary sinuses by tapping the finger tips against a finger placed over the sinuses. Intra orally, percussion is used to evaluate the teeth by tapping the teeth with mirror handle; this technique may induce pain in the area of inflammation from periodontal diseases or periapical abscess.

**AUSCULTATION-** Is the act or process of listening for sounds within the body. e.g. Auscultation to the clicking in the Temporomandibular Joint (T.M.J.) by the use of **stethoscope**.

**Auscultation technique is rarely used in Dentistry.**

**SMELLING:**Foul smelling some time with infected lesion in the orofacial region ,



## *Extra oral examination*

Assessment of the face

Start by looking at the **standing patient**. **Assess the symmetry of the face as well as the head and neck region.**

This can also be done if the patient is **sat upright in the dental chair**.

Most of us have some asymmetries, but significant asymmetries on comparison of one side to the other should be noted. **This asymmetry may be bony or soft tissue in nature.** It may be acute or chronic, or it may be secondary to previous surgery, e.g. tumour resection or CVA.

It may have occurred following injury, such as a fall, and the patient presents to the dentist with **deranged occlusion** and **facial asymmetry** due to a **mandibular fracture**.

## *Examination of the eye*

Looking at a patient's eye can give the dentist an insight into what possible systemic conditions the patient may have. Corneal arcus or xanthelasma may indicate dyslipidaemia and a possible increased risk of cardiovascular disease, diabetes or stroke. Proptosis (bulging eye) may signify endocrine disorder (Graves' disease), or occasionally even malignancy. Acute presentation of proptosis is less likely at the dental surgery, but if seen following a facial injury, it may represent a retrobulbar haemorrhage.

This is an **urgent vision threatening condition**, which **needs immediate referral to emergency department for decompression**, usually by oral and maxillofacial teams.

The eye may show signs of medical conditions already known to the patient, but if they are not known, advising the patient to seek medical attention may influence their outcome.

# Extra oral Examination

## Objectives: -

1. To evaluate any general abnormalities & in particular those of the head & neck region.
2. To look for signs & symptoms of the patient that could influence diagnosis & treatment. This examination includes:
  - \*General examination of the patient including his Posture, Gait, Facial Form, Nutritional, Status, Habits, Speech, Skin, Hair, nail, & all exposed parts of the body. \*Examination of head include T.M.J., Lymph Nodes (Submandibular, Sub mental, etc..), Salivary gland Parotid & Submandibular gland etc.), Bones of skull, Sinuses (Maxillary Sinus), ear, eyes, & peri oral tissues. Examination of neck include Thyroid gland, Lymph Nodes (Cervical node anterior & posterior) & other midline structures & muscle (The neck should be inspected for midline or lateral swelling, scar, or any inflammatory lesions palpated for Thyroid enlargement or Cervical lymph node enlargement. The T.M.J, palpated for any clicking or pain, & asking the patient to open and close the mouth to see if there is any limitation of opening (Trismus), or deviation of occlusion. The eyes should be examined for Exophthalmos or proptosis, pallor of Conjunctiva may indicate Anemia. Sclera of the eye should be also examined; Yellow discoloration may indicate Hepatitis or Obstructive Jaundice (Liver Diseases).

## **Examination of the neck**

Examination of the neck includes **inspection for any scars, masses, glandular or nodal enlargement.**

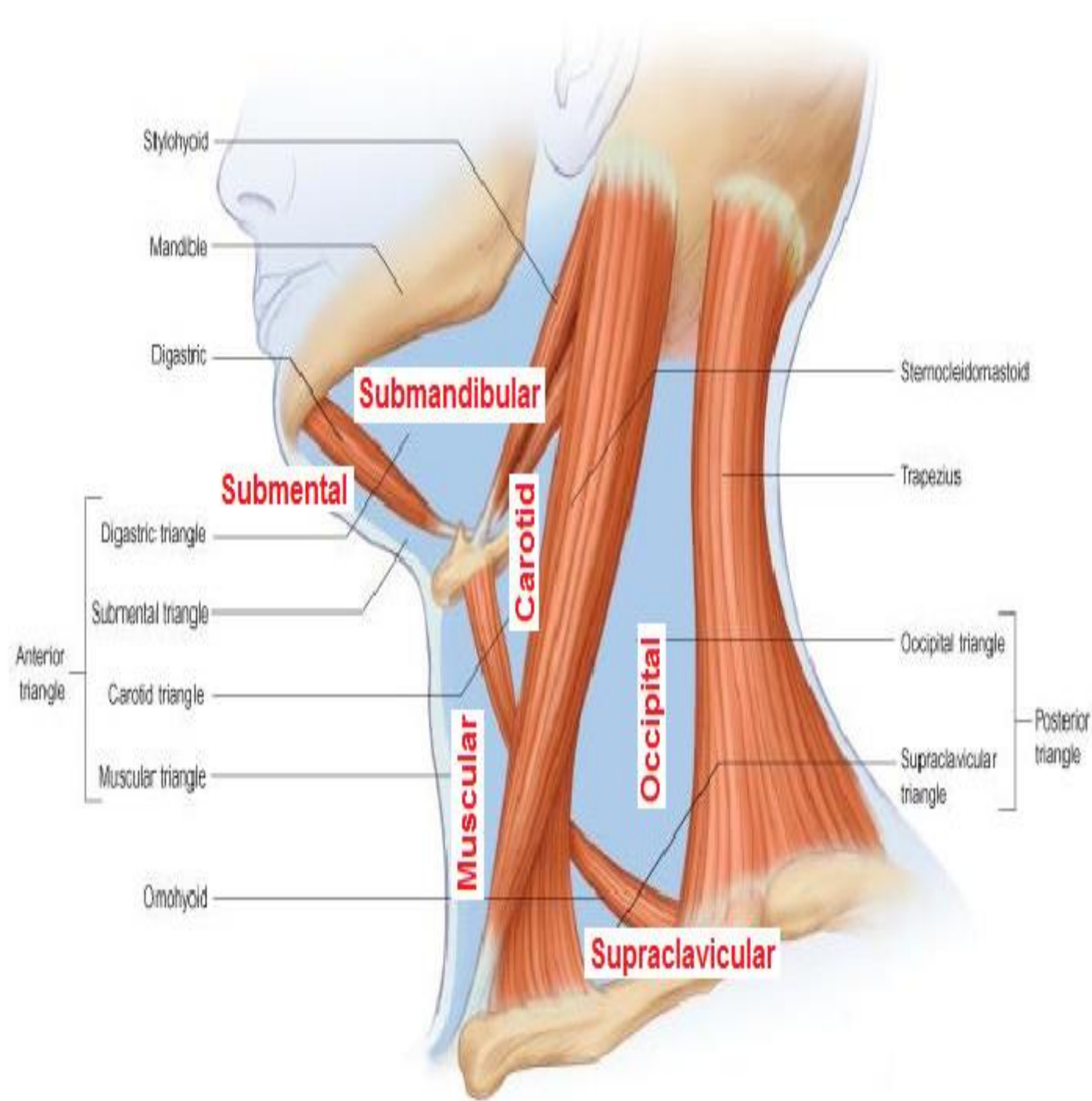
**Inspect the trachea, noting any deviation.**

Next inspect the **thyroid gland** as the patient swallows, noting any enlargement.)

Medical examination **starts with inspection**, followed by **palpation** and **percussion**.

Inspect and identify scars on the neck that may indicate previous surgery (**thyroidectomy, tracheostomy** or **neck dissection** for head and neck cancer).

**Identify any masses in the neck.**



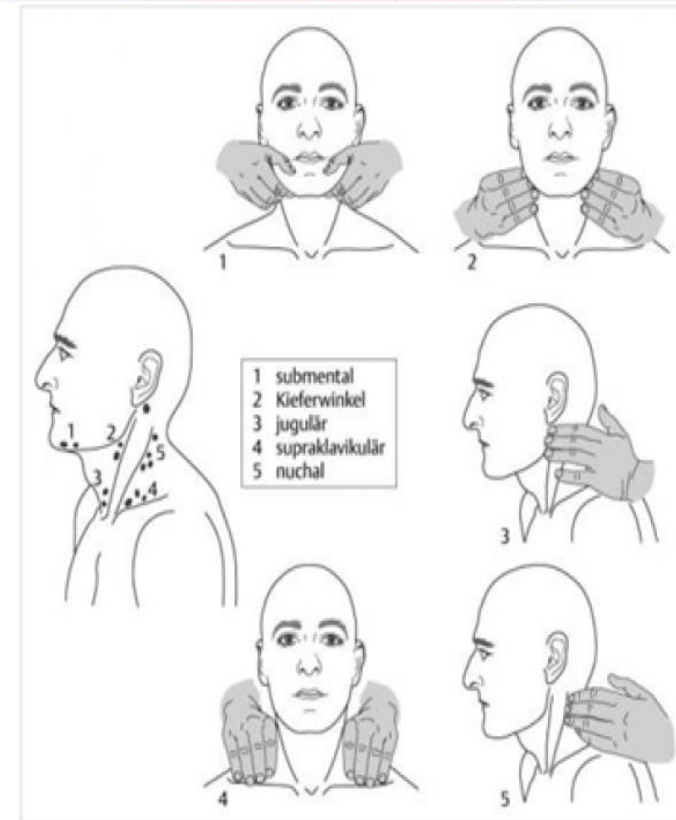
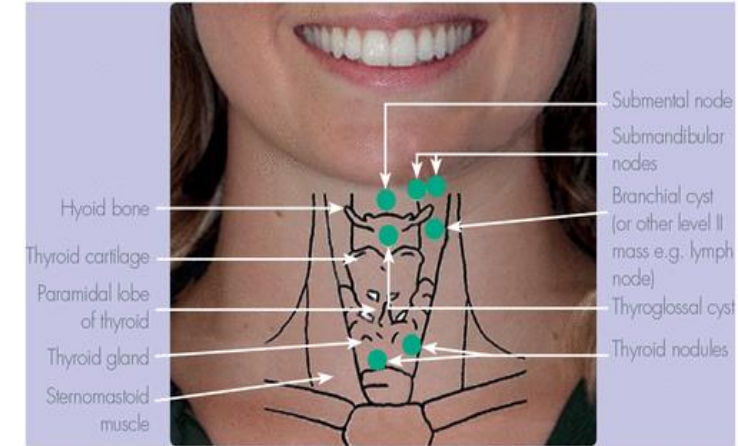
# Be very careful when you examin the cervical sewelling

- Asymmetric neck mass in adults
- Asymmetrically enlarged cervical LN (1+)
- Consider neck lump:
  - Is it malignant?
    - Assoc lesions
    - Regional lymphadenopathy
    - Rate of growth - rapid but not so fast as would suggest a cyst
    - synergy between heavy smoking and excessive drinking
    - radiation exposure
    - thyroid Ca
    - Age
      - 0 - 15: infective > developmental > neoplastic (10%; most lymphoma)
      - 15 - 55: same but more neoplastic
      - > 55: neoplastic (40%) > infctive > developmental
    - LN > 10 mm on CT : ?Ca

## Tips for the examination:

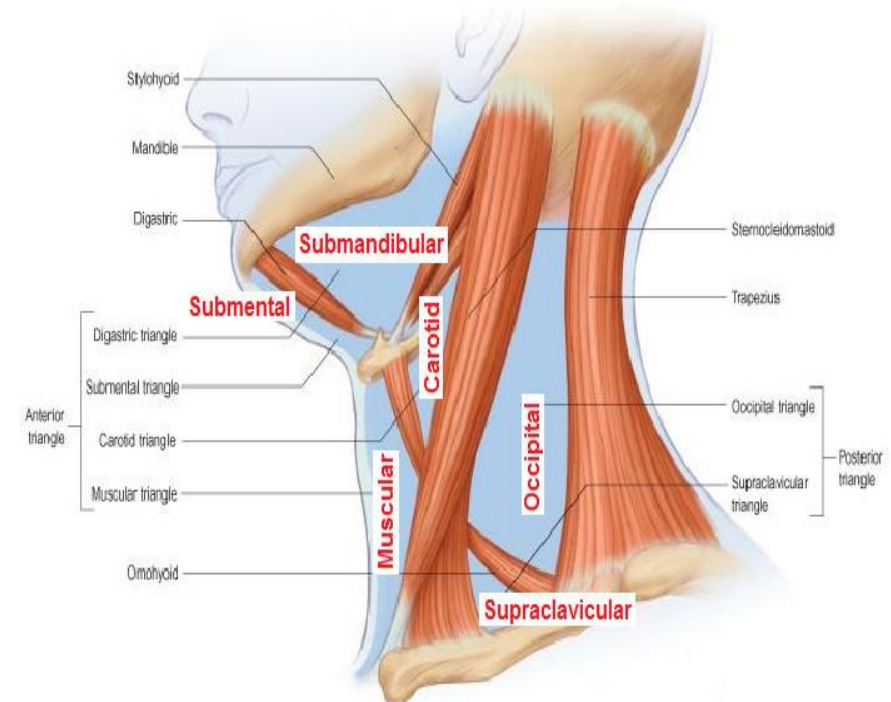
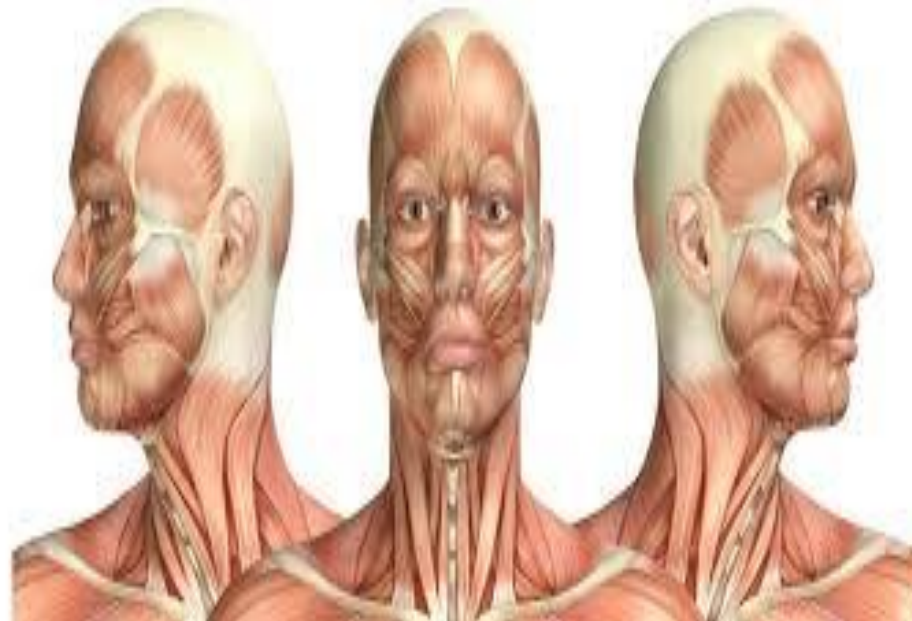
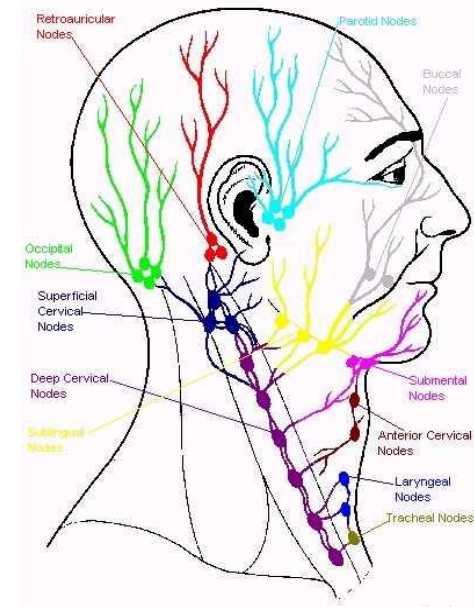
### •Palpate for:

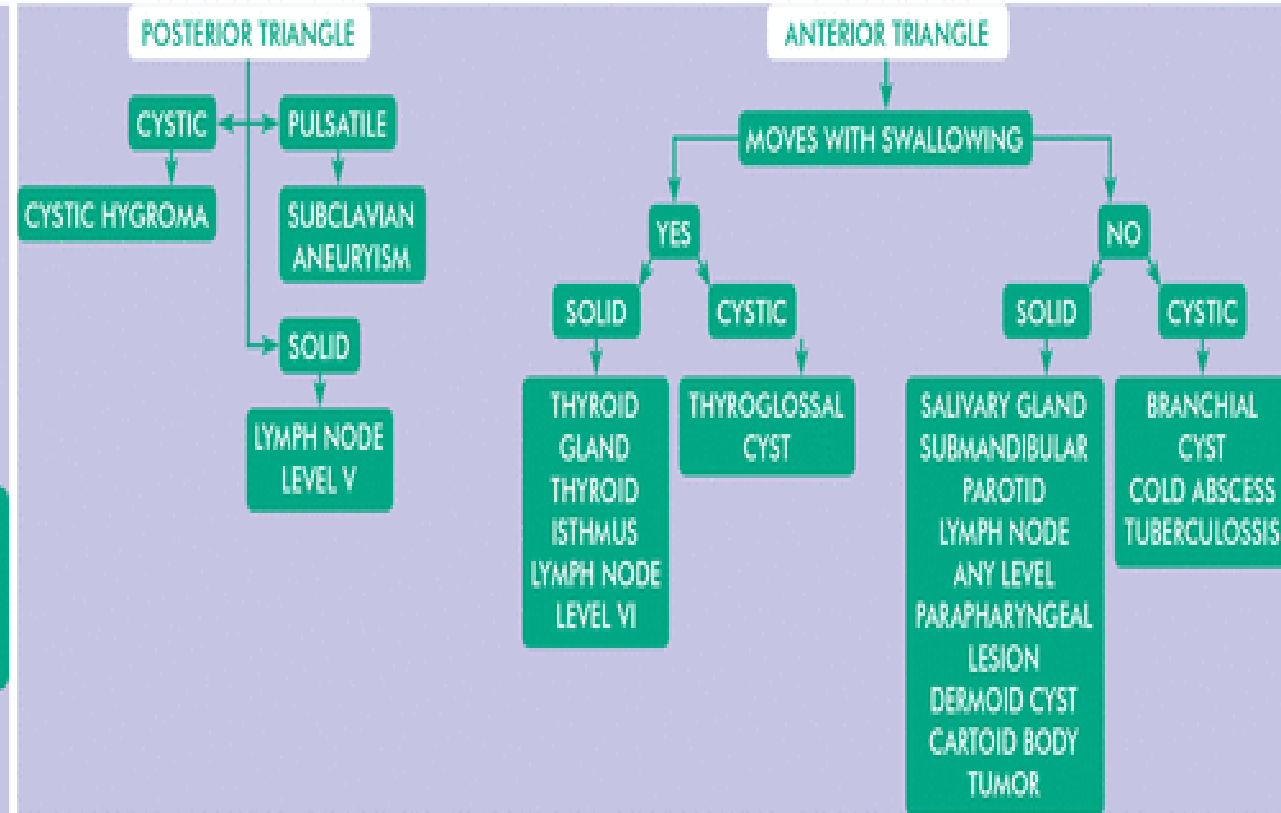
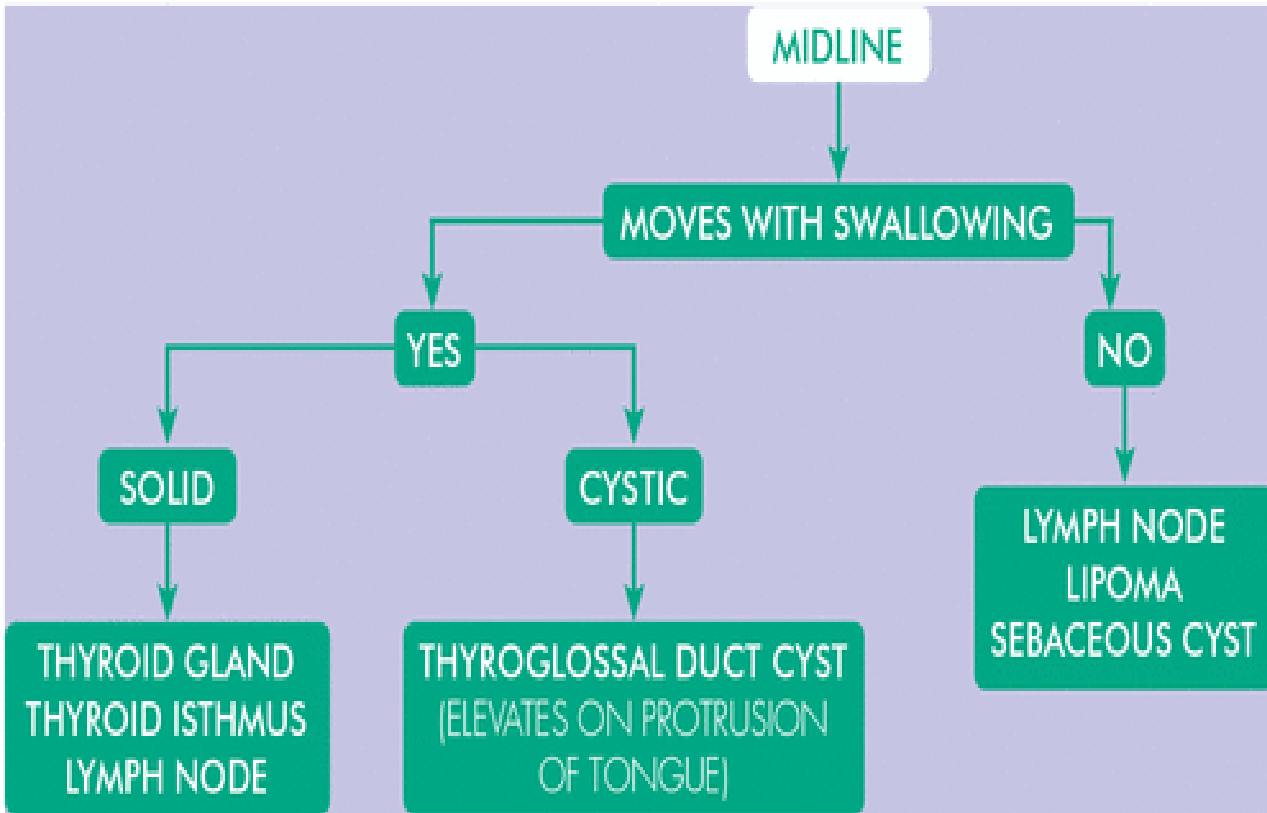
- **Size** - but doesn't give Ca risk , Location (see below)
- **Consistency** , =Hard - calcified, bone, Soft – Benign, Rubbery - LN, lymphoma, Firm – Ca, Flucuant, Pulsatile



# Anatomy gives clues to causes

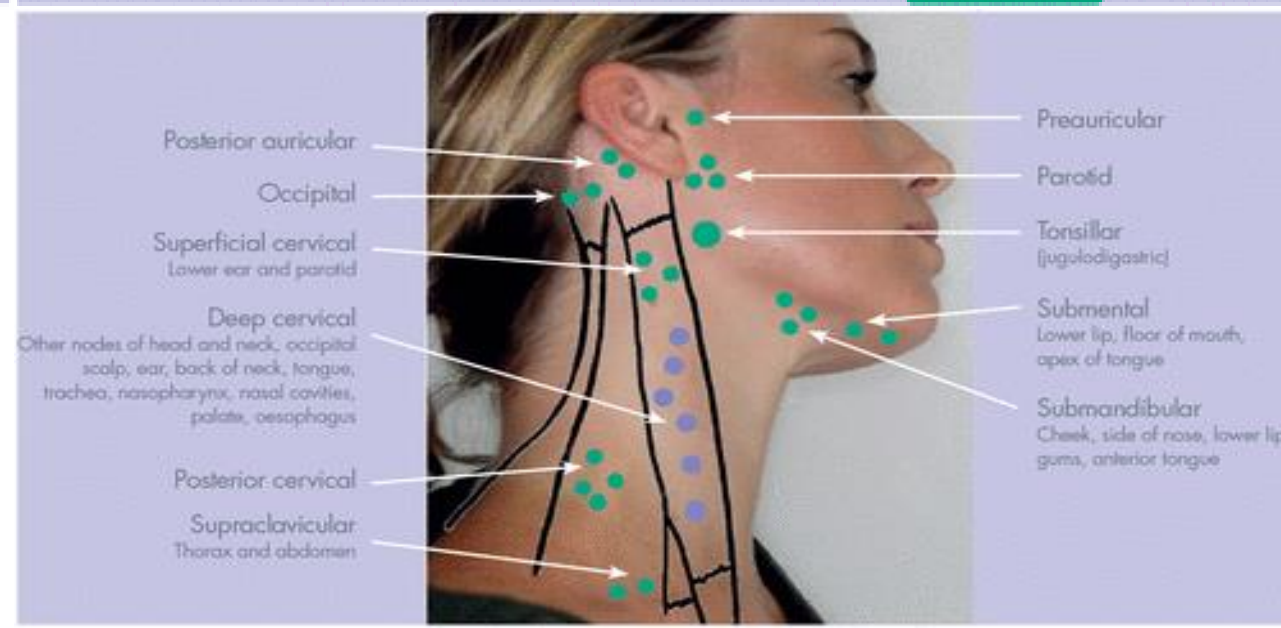
- **Submandibular**
- Submandibular gland obsn, neoplasm, inflammation, LN, Tail of parotid, Lymphangioma
- **Submental**
- Thyroglossal cyst, Dermoid cyst - as in midline, Teratoma
- Ranula - sublingual gland obsn but usually swells upward into mouth
- LN
- **Carotid**
- Branchial cyst, Neuroma Fibroma, Schwannoma, LN
- **Muscular**
- Thyroid nodules etc, Thyroglossal cyst - moves when protrude tongue, LN, Dermoid cyst - midline
- Laryngocoele, Laryngeal mass
- **Occipital**
- LN, Cystic hygroma
- **Supraclavicular**
- Virchow's node, Pancoast





# Neck lump in relation to site

Lymph nodes in anterior and posterior triangle of neck



## ***TMJ and muscles of mastication***

Examination of joints classically follows the pattern of LOOK, FEEL, and MOVE. Look for redness or swelling over the TMJ. Press gently over the **TMJ** and ask **if it is painful**.

Ask the patient to **open and close** their mouth and palpate and listen for **clicks or crepitus**. Note any **deviation in mouth opening and the side of the deviation**. The mandible often deviates to the side of pathology.

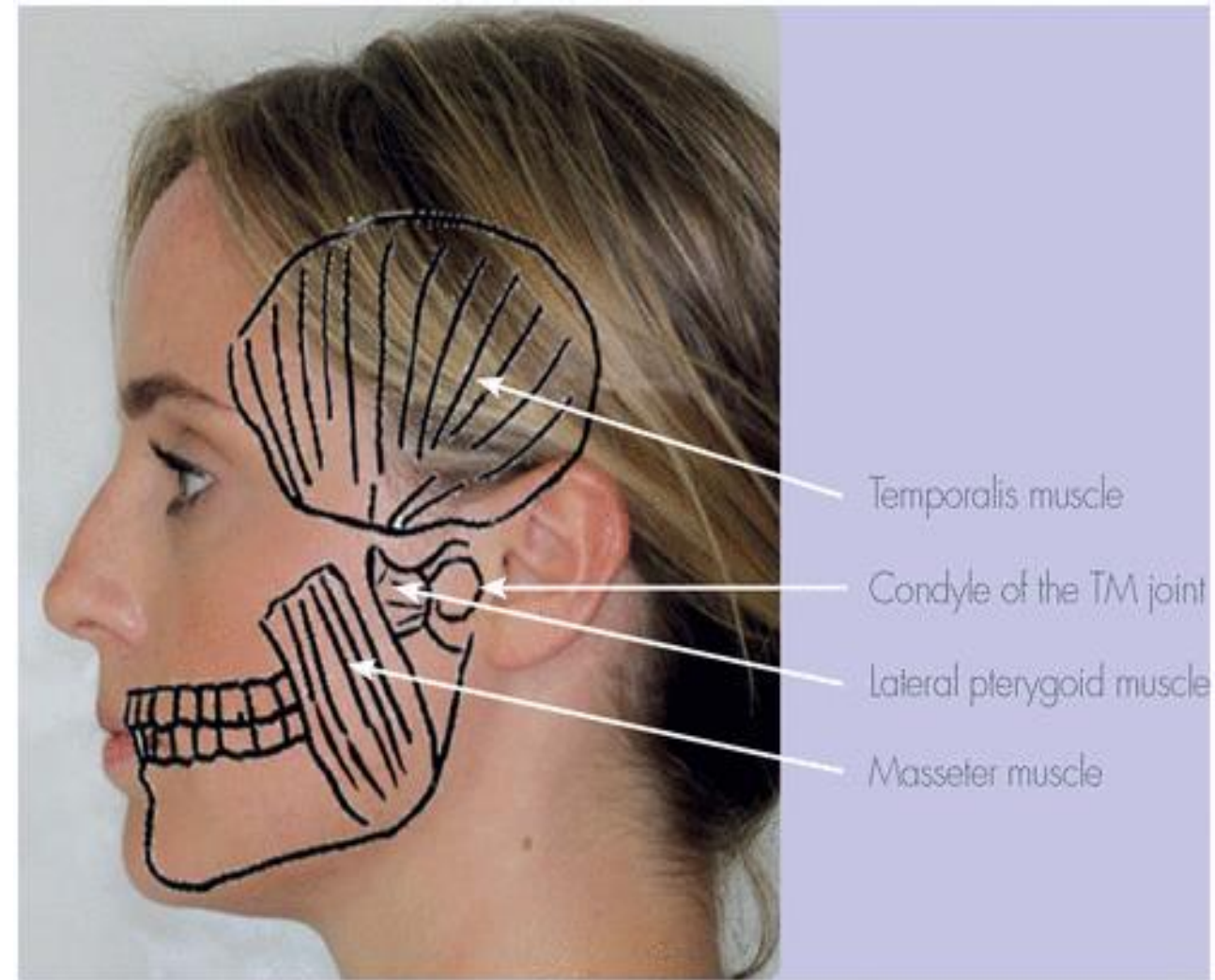
**Record any limitation in mouth opening**. Normal maximum mouth opening is **40-50mm** with **35mm opening being an acceptable range of jaw opening**.

Assess for extent of **protrusion and left and right lateral excursion**.

Note if one side is more limited than the other. Assess the masticatory muscle, the masseters, temporalis and lateral pterygoid muscles.

Request that the patient **clench and feel the bulk of the masticatory muscles** by direct palpitation for masseter and temporalis. Assessment of the inferior head of the lateral pterygoid muscles is classically carried out intra-oral by gentle palpation laterally behind the maxillary tuberosity.

**Although this is routinely carried out by many clinicians, there is some concern over its validity and reliability**



Ask the patient to **clench and palpate the masseter and temporalis muscles extra-orally**.

Ask if there is **tenderness of the muscle as you palpate**. There may be trigger points within the muscle that is more tender. Extra oral palpation of the masseter muscle provides information on the superficial fibres, whilst feeling the bulk of the masseter muscle with a finger inside the mouth and thumb on the outside provides additional information on the deep fibres.

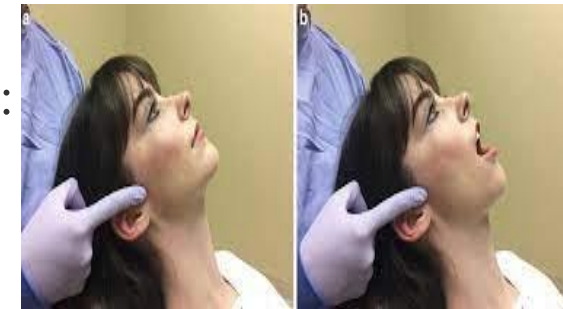**Temporomandibular disorder is characterised by one or more of the following features:**

**tenderness on palpation over the TMJ,**

**joint sounds,**

**masticatory muscle tenderness and**

**deviation mandible**, along with signs of **parafunction**: scalloping of tongue, linear abrasion on buccal mucosa, sign of tooth substance wear and **possible tooth fracture**



## **Cranial nerve examination**

The most likely cranial nerves a dentist may need to examine are the trigeminal (V) and facial (VII) cranial nerves. Infections of the mandible, including osteomyelitis, may present with altered sensation.

Objective assessment and documentation of the neurology will be important as **infection**, trauma (fractured mandible), **iatrogenic following surgery** and malignancy are all possible causes of altered sensation.

**Sensory changes** due to **infection** often improves as the infection resolves, **in contrast to malignancy**.



**A patient presenting with a swollen face likely to be a parotid swelling requires examination of the facial nerve (VII).**

The most common parotid tumour is pleomorphic adenoma, which is a benign tumour.

However, facial nerve involvement in association with a parotid mass would be suggestive of a **malignant tumour**.

**Trigeminal Nerve (V cranial nerve) provides the sensory supply to the face and motor supply to the muscles of mastication.** There are **three sensory branches of the trigeminal nerve**:

ophthalmic,

maxillary and

mandibular. The motor supply is assessed by observing and feeling the bulk of the *masseter* and *temporalis* muscles.

Power can be assessed by asking the patient to then open their mouth against resistance.

**The facial nerve (VII cranial nerve)** supplies motor branches to the muscles of facial expression.

This nerve is assessed by asking the patient to **raise their eyebrows, close their eyes and keep them closed against resistance, puff out their cheeks and reveal their teeth** .

The images show a patient with a left sided lower motor neuron facial nerve palsy as shown by the involvement of the left forehead.

There is asymmetry in the **parotid gland region with concavity on the left side indicative of previous surgery**.



**Intraoral Examination: - Objectives** 1.To detect soft tissue abnormalities. 2.To evaluate the status of teeth and other hard tissues. Intraoral examination consists of evaluation of the following areas in systematic ways: Lips, Labial & Buccal Mucosa, Muco-buccal folds, floor of the mouth, Tongue, Hard & Soft Palate, Oropharynx, Muscle of mastication (Lateral & Medial muscles), Teeth, Gingiva, Orifice of the ducts of the Parotid and Sub mandibular Glands. intra oral examination should begin with the observation of the mouth for extent or deviation. The extent of the opening its averaging between 35 – 55 mm and usually described in terms of the of the width of the patient's fingers e.g. 3 or 4 fingers opening, then we look for the oral Hygiene weather is good, fair poor, or very poor. We use the mouth mirror to reflect or retract the cheek & the lips with good light, to evaluate the condition of the vestibules, floor of the mouth, ventral surface of the tongue avoid any overlooking of these hidden areas, also the opening of the salivary glands ducts examined for enlargement, redness, & discharge. The ventral, lateral, dorsal, aspects of the tongue should be examined for the presence or absence of papillae, fissuring, ulceration, growth, indurations, limitation in extraction, & lateral movement. Hard & soft tissue examined for swelling, ulcers, sinuses, & perforation. Mucosal changes may be observed in association with Leukoplakia, Tobacco irritation, Pigmentation. The gingiva examined for the slipping, the color & the size of interdental papillae, any cause of food impaction, the presence of calculus, sinuses or retained roots, pocket etc...

13

**Teeth Examination:** The presence, absence, appearance, mobility, retained roots, retained deciduous teeth, Malposed teeth, mobility of teeth classified as nil, marked or gross Attrition (Exposed dentin), Exposed roots, Carious Lesions, Vitality test (hot & cold application, Pulp tester, etc...). The teeth might be percussed or probed with our instrument to see any tenderness or sensitivity of the teeth. Any edentulous area should be dried with a piece of cotton and examined for the presence of retained roots or discharging sinuses. Occlusion should be examined in closed and rest position the presence of open bite, type of occlusion (Neuro occlusion class I, or disto occlusion class II, or mesio occlusion class III).

**Investigations** Sometime the clinician determines that additional tests are needed to clarify some aspects of the diagnosis such tests include radiographic examination, Biopsy (Histological Study), Cytology, Aspiration, Clinical Laboratory studies.

**\*Radiographic examination:** Is one of the special methods of examination which mostly used in the Oral Surgery. It provides information about hard & soft tissues that are hidden for eye which aid in diagnosis & to evaluate the progress of the disease. For example, Peri apical, occlusal, & extra oral views like lateral oblique of the Mandible radiograph. CT scan, MRI

**•VITALITY TEST: -**

1. Hot application (e.g. Hot instrument)
2. Cold application (e.g. Ethyl Chloride Application)
3. Electrical pulp Tester. Used to check the vitality or response of teeth.

**BIOPSY:** Small pieces of tissue taken from the lesion submitted to microscopical examination (Histopathology examination).

Biopsy could be incisional or Excisional, Exfoliate

Cytology. It is used to confirm the diagnosis of the lesion. **•ASPIRATION:** - the withdrawal of fluid from the lesion may aid in diagnosis. For example, aspiration of pus indicates an inflammatory process like abscess or in infected cyst. Aspiration of yellow fluid may indicate cystic lesion, aspiration of blood may indicate Vascular lesion like Hemangioma, etc.... Aspiration is one of the methods used to aspirate fluid from swelling for evaluation the nature of that swelling which may assist in Diagnosis.

**LABORATORY TEST: -**

**LIKE** 1. bacteriological examination. 2. Hematological examination 3. Urine analysis (GUE) 4. Blood Chemistry & Serological examination. 5. Culture & sensitivity test.

All these tests or any one of these tests might be ordered to aid as in **confirming our Diagnosis.**

So, collection of all information taken from the history & clinical examination & accessory information (Special tests) must be evaluated, analyzed to **reach the final Diagnosis.**

**•PATIENT RECORD (MEDICAL) RECORD: -**

It consists of: - 1. Case sheet. 2. All radiographs. 3. All investigation papers. 4. Referring papers.

**Objectives & Benefits:** 1. It assist in Diagnosis of the diseases. 2. For follow up & future checking. 3. For statistical analysis. 4. For studies & educations. 5. For Medico legal purposes.

